

## MEDICAL POLICY – 7.01.592

## Surgical Treatment of Femoroacetabular Impingement

BCBSA Ref. Policy: 7.01.118

Effective Date: Jul. 1, 2025

Last Revised: Jun. 23, 2025

Replaces: N/A

RELATED MEDICAL POLICIES:

7.01.142 Surgery for Groin Pain in Athletes

Select a hyperlink below to be directed to that section.

[POLICY CRITERIA](#) | [DOCUMENTATION REQUIREMENTS](#) | [CODING](#)  
[RELATED INFORMATION](#) | [EVIDENCE REVIEW](#) | [REFERENCES](#) | [HISTORY](#) | [APPENDIX](#)



Clicking this icon returns you to the hyperlinks menu above.

## Introduction

Femoroacetabular impingement (FAI) is when the bones in your hip joint are not shaped normally or are growing in a way that makes them rub together or pinch when you move. This can cause pain or limit your range of motion. When you have tried physical therapy and medications to make you feel better, but they do not work, you may need surgery. Surgery can help relieve pain, improve hip motion, and stop further damage to your hip joint. One way to do this surgery is arthroscopically, which is when the surgeon uses a camera and a specialized instrument to reshape the bone and repair damage. If your condition is more complex, the surgeon may opt for an open hip surgery. This policy explains when arthroscopic surgery to treat FAI is considered medically necessary.

**Note:** The Introduction section is for your general knowledge and is not to be taken as policy coverage criteria. The rest of the policy uses specific words and concepts familiar to medical professionals. It is intended for providers. A provider can be a person, such as a doctor, nurse, psychologist, or dentist. A provider also can be a place where medical care is given, like a hospital, clinic, or lab. This policy informs them about when a service may be covered.

## Policy Coverage Criteria

Treatment	Medical Necessity
<b>Arthroscopic treatment of femoroacetabular impingement</b>	<p><b>Arthroscopic treatment of femoroacetabular impingement (FAI) may be medically necessary when ALL of the following conditions have been met:</b></p> <ul style="list-style-type: none"> <li>• Age <ul style="list-style-type: none"> <li>○ Candidates should be skeletally mature with documented closure of growth plates (e.g., greater than or equal to 15 years of age).</li> </ul> </li> </ul> <p><b>AND</b></p> <ul style="list-style-type: none"> <li>• Symptoms <ul style="list-style-type: none"> <li>○ Moderate-to-severe hip pain worsened by flexion activities (e.g., squatting or prolonged sitting) that significantly limits activities; <b>and</b></li> <li>○ Unresponsive to conservative therapy for at least 3 months (including activity modifications, restriction of athletic pursuits, and avoidance of symptomatic motion); <b>and</b></li> <li>○ Positive impingement signs on clinical examination (pain elicited with 90° of flexion and internal rotation and adduction of the femur/FADIR test) or FABER (Patrick's) test. (See <a href="#">Appendix</a>)</li> </ul> </li> </ul> <p><b>AND</b></p> <ul style="list-style-type: none"> <li>• Imaging (X-rays, MRI, or CT scan) evidence of FAI morphology: partial, or full thickness labral tearing and/or articular cartilage damage with <b>ONE</b> or more of the following indicators of cam or pincer FAI: (See <a href="#">Appendix</a>) <ul style="list-style-type: none"> <li>○ Acetabular retroversion (overcoverage with crossover sign)</li> <li>○ Coxa profunda or protrusion</li> <li>○ Damage of the acetabular rim</li> <li>○ Femoral head-neck offset with an alpha angle &gt; 50°</li> <li>○ Pistol grip deformity</li> <li>○ Positive wall sign</li> </ul> </li> </ul> <p><b>AND</b></p> <ul style="list-style-type: none"> <li>○ No evidence of advanced osteoarthritis, defined as Tönnis grade 2 or 3, or joint space of less than 2 mm; <b>and</b></li> <li>○ No evidence of severe (Outerbridge grade IV) chondral (cartilage) damage</li> </ul>

Treatment	Medical Necessity
	<p><b>Note:</b> (See <a href="#">Definition of Terms</a>)</p> <p><b>Hip arthroscopic repair of a labral tear is considered medically necessary either alone or as an adjunct to FAI surgery.</b></p> <p><b>Arthroscopic treatment of FAI is considered investigational in all other situations not outlined in the Medical Necessity section above.</b></p>

### Documentation Requirements

**The individual's medical records submitted for review for all conditions should document that medical necessity criteria are met. The record should include the following:**

- Office visit notes that contain the relevant history and physical (including the individual's symptoms, the conservative measures trialed and failed, and a positive impingement sign on physical examination)

**AND**

- Imaging evidence of morphology of FAI: partial or full thickness labral tearing and/or articular damage with one or more of the following indicators of cam or pincer FAI:
  - Acetabular retroversion (over coverage with crossover sign)
  - Coxa profunda or protrusion
  - Damage of the acetabular rim
  - Femoral head-neck offset with an alpha angle  $>50^{\circ}$
  - Pistol grip deformity
  - Positive wall sign

**AND**

- No evidence of advanced osteoarthritis such as Tönnis grade 2 or 3, or joint space of less than 2 mm

**AND**

- No evidence of severe chondral (cartilage) damage (Outerbridge grade IV)

### Coding

Code	Description
<b>CPT</b>	
29914	Arthroscopy, hip, surgical; with femoroplasty (i.e., treatment of cam lesion)
29915	Arthroscopy, hip, surgical; with acetabuloplasty (i.e., treatment of pincer lesion)

**Note:** CPT codes, descriptions and materials are copyrighted by the American Medical Association (AMA). HCPCS codes, descriptions and materials are copyrighted by Centers for Medicare Services (CMS).

## Related Information

### Definition of Terms

**Acetabular retroversion (over coverage with crossover sign)** is a variety of hip dysplasia. It is a condition where the acetabulum (the hip socket) faces backwards (retroversion) rather than forwards, resulting in excessive coverage of the femoral head. It is a form of pincer morphology.

**Coxa profunda** refers to a deep acetabular pocket (increased acetabular depth) where the acetabular fossa is touching or projecting medial (towards the middle) to the ilioischial line (an anatomical landmark on pelvic radiographs and characteristic of hip morphology). It is more common in females and may indicate pincer morphology.

**Damage of the acetabular rim** is damage to the outer surface of the acetabulum (the hip socket) around the femoral head.

**FADIR test:** The FADIR test stands for flexion, adduction, and internal rotation. These three motions combined result in a clinical pain provocation test to find pathologies of the lumbar spine. This tests the positive side with the hip that is symptomatic. If it is listed as positive, then the exam meets the requirement of pain with exam.

**FABER test:** The (Patrick's) FABER test stands for flexion, abduction and external rotation. These three motions combined result in a clinical pain provocation test to find pathologies at the hip, lumbar, and sacroiliac region. This is generally positive when there is arthritis in the hip. It should generally be negative for some people being examined for FAI.

**Femoral head-neck offset with an alpha angle  $>50^\circ$**  is a quantitative characterization of hip morphology used to determine the femoral head-neck junction used in preoperative planning

for FAI. Initially, in 2002 an alpha angle  $>50^\circ$  was proposed as pathological. This higher value is thought to be associated with cam-type impingement.

## Outerbridge Classification

Grade	Pathology
0	Normal cartilage
I	Softening and swelling of articular cartilage
II	Fragmentation and fissuring of articular cartilage affecting an area of less than 0.5 inches
III	Fragmentation and fissuring of articular cartilage affecting an area of greater than 0.5 inches
IV	Cartilage erosion to bone

**Pistol grip deformity** is a flattening of the femoral head-neck junction. It may also be seen as a decreased head/neck offset on pelvic radiographs. The term came from the shape of the femur resembling a pistol seen in old movies. It is indicative of cam morphology and is more common in men than women.

**Positive posterior wall sign** is when the posterior acetabular wall lies medial to the center of the femoral head. It is a radiographic sign used to assess the morphology of FAI.

**The Tönnis Classification System** is commonly used to describe the radiographic presence of osteoarthritis in the hips with grading as follows:

- **Grade 0:** No signs of osteoarthritis
- **Grade 1:** Sclerosis of the joint with slight joint space narrowing and osteophyte formation, and no or slight loss of femoral head sphericity
- **Grade 2:** Small cysts in the femoral head or acetabulum with moderate joint space narrowing and moderate loss of femoral head sphericity
- **Grade 3:** Large cysts in the femoral head or acetabulum, severe joint space narrowing or obliteration of the joint space, and severe deformity and loss of sphericity of the femoral head

If femoroacetabular impingement morphology is identified, individuals should be advised not to play aggressive sports. No more frequent than annual follow-up with magnetic resonance arthrography may be indicated for femoroacetabular impingement morphology to evaluate

cartilage changes before damage becomes severe. It should be noted that current imaging techniques limit the early identification of cartilage defects, whereas delay in the surgical correction of bony abnormalities may lead to disease progression to the point at which joint preservation is no longer appropriate. Confirmation of subtle femoroacetabular impingement morphology may require 3-dimensional computed tomography. Some clinicians may also use local anesthetic injection into the joint to assist in confirming femoroacetabular impingement pathology.

Treatment of femoroacetabular impingement should be restricted to centers experienced in treating this condition and staffed by surgeons adequately trained in techniques addressing femoroacetabular impingement. Because of the differing benefits and risks of open and arthroscopic approaches, individuals should make an informed choice between the procedures.

Some individuals may require a revision procedure if symptoms recur or persist. Published studies have indicated that all sources of impingement might not have been identified before surgery, and those that had might not have been adequately treated. The risk of additional surgical procedures can be reduced by intraoperative assessment of impingement after bone debridement and reshaping.

## Consideration of Age

The age range listed in this policy takes into consideration skeletal maturity. Skeletal maturity is reached in adolescence around the age of 15.

## Evidence Review

---

### Description

Femoroacetabular impingement results from localized compression within the joint as a result of an anatomic mismatch between the head of the femur and the acetabulum. Symptoms of impingement typically occur in young to middle-aged adults before the onset of osteoarthritis but may be present in younger individuals with developmental hip disorders. The objective of surgical treatment of femoroacetabular impingement is to provide symptom relief and reduce further joint damage.

## Background

### Femoroacetabular Impingement

Femoroacetabular impingement arises from an anatomic mismatch between the head of the femur and the acetabulum, causing compression of the labrum or articular cartilage during flexion. The mismatch can arise from subtle morphologic alterations in the anatomy or orientation of the ball-and-socket components (e.g., a bony prominence at the head-neck junction or acetabular over coverage), with articular cartilage damage initially occurring from abutment of the femoral neck against the acetabular rim, typically at the anterosuperior aspect of the acetabulum. Although hip joints can possess the morphologic features of femoroacetabular impingement without symptoms, femoroacetabular impingement may become pathologic with repetitive movement and/or increased force on the hip joint. High-demand activities may also result in pathologic impingement in hips with normal morphology.

Two types of impingements, cam, and pincer, may occur alone or, more frequently, together. Cam impingement is associated with an asymmetric or nonspherical contour of the head or neck of the femur jamming against the acetabulum, resulting in cartilage damage and delamination (detachment from the subchondral bone). Deformity of the head/neck junction that looks like a pistol-grip on radiographs is associated with damage to the anterosuperior area of the acetabulum. Symptomatic cam impingement is found most frequently in young male athletes. Pincer impingement is associated with over coverage of the acetabulum and pinching of the labrum, with pain more typically beginning in women of middle age. In cases of isolated pincer impingement, the damage may be limited to a narrow strip of the acetabular cartilage.

Epidemiologic and radiographic studies have found correlations between hip osteoarthritis and femoroacetabular impingement lesions, supporting the theory that prolonged contact between the anatomically mismatched acetabulum and femur may lead not only to cam and pincer lesions but also to further cartilage damage and subsequent joint deterioration. It is believed that osteoplasty of the impinging bone is needed to protect the cartilage from further damage and to preserve the natural joint. Therefore, if femoroacetabular impingement morphology is shown to be an etiology of osteoarthritis, a strategy to reduce the occurrence of idiopathic hip osteoarthritis could be early recognition and treatment of femoroacetabular impingement before cartilage damage and joint deterioration occurs.

An association between femoroacetabular impingement and athletic pubalgia, sometimes called sports hernia, has been proposed. Athletic pubalgia is an umbrella term for a large variety of musculoskeletal injuries involving attachments and/or soft tissue support structures of the pubis (See [Related Policies](#)).

## **Treatment**

A technique for hip dislocation with open osteochondroplasty that preserved the femoral blood supply was reported by Ganz. Visualization of the entire joint with this procedure led to the identification and acceptance of femoroacetabular impingement as an etiology of cartilage damage and the possibility of correcting the abnormal femoroacetabular morphology. Open osteochondroplasty of bony abnormalities and treatment of the symptomatic cartilage defect is considered the criterion standard for complex bony abnormalities. However, open osteochondroplasty is invasive, requiring transection of the greater trochanter (separation of the femoral head from the femoral shaft) and dislocation of the hip joint to provide full access to the femoral head and acetabulum. In addition to the general adverse events of open surgical procedures, open osteochondroplasty with dislocation has been associated with nonunion and neurologic and soft tissue lesions.

Less invasive hip arthroscopy and an arthroscopy-assisted mini-approach were developed by 2004. Arthroscopy requires specially designed instruments and is considered technically more difficult due to reduced visibility and limited access to the joint space. Advanced imaging techniques, including computed tomography and fluoroscopy, have been used to improve visualization of the 3-dimensional head/neck morphology during arthroscopy.

Femoroacetabular impingement can also be a source of hip pain and decreased hip internal rotation in the pediatric population. When nonoperative management of femoroacetabular impingement in children and adolescents is ineffective, surgical procedures may be indicated. Surgical techniques include arthroscopy, open hip dislocation, limited open with arthroscopy, and osteotomy.

## **Slipped Capital Femoral Epiphysis**

Individuals with slipped capital femoral epiphysis have a displaced femoral head in relation to the femoral neck within the confines of the acetabulum, which can result in hip pain, thigh pain, knee pain, and the onset of a limp. Slipped capital femoral epiphysis occurs most frequently in children between the ages of 10 to 16. Upon reaching skeletal maturity, 32% of individuals diagnosed with slipped capital femoral epiphysis were found to have clinical signs of impingement. It is not uncommon for individuals with slipped capital femoral epiphysis to develop premature osteoarthritis and require total hip arthroplasty within 20 years.





## Treatment

The standard treatment for slipped capital femoral epiphysis is stabilization across the physis by in situ pinning. Alternative treatments proposed for pediatric individuals with slipped capital femoral epiphysis-related femoroacetabular impingement include osteoplasty without dislocation, or with the open dislocation technique described by Ganz. The Ganz technique (capital realignment with open dislocation) is technically demanding, with a steep learning curve and a high-risk of complications, including avascular necrosis. Therefore, early treatment to decrease impingement must be weighed against the increased risk of adverse events.

## Summary of Evidence

For individuals who are adults with asymptomatic femoroacetabular impingement who receive femoroacetabular impingement surgery, there is no direct evidence that the surgical treatment will prevent the development of osteoarthritis. Relevant outcomes are symptoms, functional outcomes, health status measures, quality of life, and change in disease status. Indirect evidence consists of observational studies. In retrospective studies of individuals with osteoarthritis, the relevant outcomes were radiographic evidence of hip joint malformations. In prospective studies of individuals with femoroacetabular impingement, the relevant outcome is progression to osteoarthritis. Several large observational studies (> 1000 individuals), as well as smaller studies, have shown radiographic evidence of relationships between abnormal hip morphology and the development of osteoarthritis. There have been no studies in which femoroacetabular impingement surgery was performed on individuals with femoroacetabular impingement morphology but no symptoms. The evidence is insufficient to determine that the technology results in an improvement in the net health outcome.

For individuals who are adults with symptomatic femoroacetabular impingement who receive femoroacetabular impingement surgery, the evidence includes mostly systematic reviews of large and small observational studies and systematic reviews of randomized control trials (RCTs). Relevant outcomes are symptoms, functional outcomes, health status measures, quality of life, and change in disease status. Open hip dislocation surgery and arthroscopic surgery are the most common surgical techniques performed on individuals with femoroacetabular impingement. Systematic reviews have evaluated open hip dislocation surgery and arthroscopic surgery, compared with no comparator, nonsurgical management, and other surgical techniques. Compared with nonsurgical management, all types of surgical techniques have resulted in significant improvements in functional outcomes, pain, and radiographic measurements. The reviews were limited when comparing surgical techniques with each other because individual characteristics and outcome measurements were heterogeneous among

studies. The evidence is sufficient to determine that the technology results in an improvement in the net health outcome.

For individuals who are children 15 years of age or younger with symptomatic femoroacetabular impingement who receive femoroacetabular impingement surgery, the evidence includes a meta-analysis evaluating small observational studies and individual observational studies. Relevant outcomes are symptoms, functional outcomes, health status measures, quality of life, and change in disease status. While the studies reported reductions in pain and improvements in functional outcomes, the sample sizes were relatively small, ranging between 11 and 116 hips per study. Additionally, comparative studies were not identified. The evidence is insufficient to determine that the technology results in an improvement in the net health outcome.

For individuals who are children 15 years of age or younger with slipped capital femoral epiphysis-associated femoroacetabular impingement who receive femoroacetabular impingement surgery, the evidence includes a systematic review and small observational studies (range, 19 to 51 individuals). Relevant outcomes are symptoms, functional outcomes, health status measures, quality of life, and change in disease status. While most individuals experienced symptom relief following femoroacetabular impingement surgery, the surgery is invasive and complications (e.g., nonunions) were reported. The evidence is insufficient to determine that the technology results in an improvement in the net health outcome.

For individuals who have residual femoroacetabular impingement symptoms following a primary surgery who receive revision arthroscopic surgery, the evidence includes systematic reviews of observational studies (>400 individuals). Relevant outcomes are symptoms, functional outcomes, health status measures, quality of life, and change in disease status. Though the studies were of low-quality, consistent improvements in functional outcomes, pain relief, and individual satisfaction were reported, in some cases beyond 3 years. The evidence is sufficient to determine that the technology results in an improvement in the net health outcome.

## Ongoing and Unpublished Clinical Trials

Some currently ongoing and unpublished trials that might influence this review are listed in [Table 1](#).

**Table 1. Summary of Key Trials**

NCT No.	Trial Name	Planned Enrollment	Completion Date
<b>Ongoing</b>			
<a href="#">NCT04243447</a>	Identification of Predictors for Clinical Outcomes in Femoroacetabular Impingement Surgery (DoD FAI-2)	800	Sep 2025
<a href="#">NCT02692807</a>	Arthroscopic Surgical Procedures Versus Sham Surgery for Patients with Femoroacetabular Impingement and/or Labral Tears: A Multicenter, International, Double-Blinded, Randomized Controlled Trial (HIPARTI)	140	Dec 2035
<a href="#">NCT05746533<sup>a</sup></a>	A Comparison of Total Hip Arthroplasty and Hip Preservation Outcomes	10,000	June 2053 (recruiting)

NCT: national clinical trial. <sup>a</sup> Denotes industry-sponsored or cosponsored trial.

## Clinical Input Received from Physician Specialty Societies and Academic Medical Centers

While the various physician specialty societies and academic medical centers may collaborate with and make recommendations during this process, through the provision of appropriate reviewers, input received does not represent an endorsement or position statement by the physician specialty societies or academic medical centers, unless otherwise noted.

### 2009 Input

In response to requests, input was received from 2 physician specialty societies (3 reviewers) and 2 academic medical centers while this policy was under review in 2009. All input supported the use of open or arthroscopic surgery as an appropriate treatment for femoroacetabular impingement in selected individuals when conservative treatment has failed.

## Practice Guidelines and Position Statements

The purpose of the following information is to provide reference material. Inclusion does not imply endorsement or alignment with the policy conclusions.

Guidelines or position statements will be considered for inclusion if they were issued by, or jointly by, a US professional society, an international society with US representation, or the National Institute for Health and Care Excellence (NICE). Priority will be given to guidelines that are informed by a systematic review, include strength of evidence ratings, and include a description of management of conflict of interest.

### American Academy of Orthopaedic Surgeons

In 2020, the American Academy of Orthopaedic Surgeons published a consensus-based best practice guidelines checklist for preoperative, intraoperative, and postoperative hip arthroscopy considerations in individuals with femoroacetabular impingement.<sup>46</sup>

The guidelines define conservative care treatment as a trial of rest, trial of non-steroidal anti-inflammatory drugs, activity modification or restriction, and physical therapy - without concomitant use of opioids. Prior to completion of the full duration of conservative treatment, assessment of the following joint parameters is recommended: high alpha angle, low Tönnis grade, cam or combined impingement, large range of motion limitations with pain, high baseline mental health status, large cam ( $>65^\circ$  alpha angle) or combined deformity in absence of osteoarthritis changes. A shorter duration of conservative treatment is permissible in professional or out-of-season athletes, individuals completing physical therapy with no or marginal improvement, high baseline mental health status, and/or successful surgery on the contralateral side. Contraindications for hip arthroscopy include joint space narrowing  $<2$  mm along the sourcil or osteoarthritis, Tönnis grade 2 or higher, severe femoral retroversion or anteversion with gait abnormality, obesity hindering access, broken Shenton line, pain not localizing to the hip or out of proportion due to psychiatric issue, inclination Tönnis angle  $>13$  to  $15^\circ$ , or failed arthroscopy with dysplastic features. Hypermobility (Beighton Hypermobility Score  $\geq 5$ ) is not considered a contraindication for hip arthroscopy.

### National Institute for Health and Care Excellence

In 2011, the NICE issued guidance on arthroscopic femoroacetabular surgery for hip impingement syndrome.<sup>47</sup> The NICE considered the evidence on the efficacy of arthroscopic

femoroacetabular surgery for hip impingement syndrome to be adequate for symptom relief in the short and medium term.

The NICE (2011) guidance on open femoroacetabular surgery for hip impingement syndrome indicated that evidence for this procedure was adequate for symptom relief in the short and medium term.<sup>48</sup>

## Medicare National Coverage

There is no national coverage determination.

## Regulatory Status

Surgery for treatment of femoroacetabular impingement is a procedure and, as such, is not subject to regulation by the US Food and Drug Administration.

## References

1. Egger AC, Frangiamore S, Rosneck J. Femoroacetabular Impingement: A Review. *Sports Med Arthrosc Rev.* Dec 2016; 24(4): e53-e58. PMID 27811519
2. Frank JM, Harris JD, Erickson BJ, et al. Prevalence of Femoroacetabular Impingement Imaging Findings in Asymptomatic Volunteers: A Systematic Review. *Arthroscopy.* Jun 2015; 31(6): 1199-204. PMID 25636988
3. Oner A, Koksall A, Sofu H, et al. The prevalence of femoroacetabular impingement as an aetiologic factor for end-stage degenerative osteoarthritis of the hip joint: analysis of 1,000 cases. *Hip Int.* 2016; 26(2): 164-8. PMID 26916653
4. Thomas GE, Palmer AJ, Batra RN, et al. Subclinical deformities of the hip are significant predictors of radiographic osteoarthritis and joint replacement in women. A 20 year longitudinal cohort study. *Osteoarthritis Cartilage.* Oct 2014; 22(10): 1504-10. PMID 25047637
5. Reichenbach S, Leunig M, Werlen S, et al. Association between cam-type deformities and magnetic resonance imaging-detected structural hip damage: a cross-sectional study in young men. *Arthritis Rheum.* Dec 2011; 63(12): 4023-30. PMID 21904996
6. Gosvig KK, Jacobsen S, Sonne-Holm S, et al. Prevalence of malformations of the hip joint and their relationship to sex, groin pain, and risk of osteoarthritis: a population-based survey. *J Bone Joint Surg Am.* May 2010; 92(5): 1162-9. PMID 20439662
7. Takeyama A, Naito M, Shiramizu K, et al. Prevalence of femoroacetabular impingement in Asian patients with osteoarthritis of the hip. *Int Orthop.* Oct 2009; 33(5): 1229-32. PMID 19277653



8. Bardakos NV, Villar RN. Predictors of progression of osteoarthritis in femoroacetabular impingement: a radiological study with a minimum of ten years follow-up. *J Bone Joint Surg Br.* Feb 2009; 91(2): 162-9. PMID 19190047
9. Kim KC, Hwang DS, Lee CH, et al. Influence of femoroacetabular impingement on results of hip arthroscopy in patients with early osteoarthritis. *Clin Orthop Relat Res.* Mar 2007; 456: 128-32. PMID 17106273
10. Beck M, Kalhor M, Leunig M, et al. Hip morphology influences the pattern of damage to the acetabular cartilage: femoroacetabular impingement as a cause of early osteoarthritis of the hip. *J Bone Joint Surg Br.* Jul 2005; 87(7): 1012-8. PMID 15972923
11. Tanzer M, Noiseux N. Osseous abnormalities and early osteoarthritis: the role of hip impingement. *Clin Orthop Relat Res.* Dec 2004; (429): 170-7. PMID 15577483
12. Reiman MP, Peters S, Sylvain J, et al. Femoroacetabular impingement surgery allows 74% of athletes to return to the same competitive level of sports participation but their level of performance remains unreported: a systematic review with meta-analysis. *Br J Sports Med.* Aug 2018; 52(15): 972-981. PMID 29581142
13. Wall PD, Brown JS, Parsons N, et al. Surgery for treating hip impingement (femoroacetabular impingement). *Cochrane Database Syst Rev.* Sep 08 2014; 2014(9): CD010796. PMID 25198064
14. Harris JD, Erickson BJ, Bush-Joseph CA, et al. Treatment of femoroacetabular impingement: a systematic review. *Curr Rev Musculoskelet Med.* Sep 2013; 6(3): 207-18. PMID 23743861
15. Bedi A, Chen N, Robertson W, et al. The management of labral tears and femoroacetabular impingement of the hip in the young, active patient. *Arthroscopy.* Oct 2008; 24(10): 1135-45. PMID 19028166
16. Espinosa N, Rothenfluh DA, Beck M, et al. Treatment of femoro-acetabular impingement: preliminary results of labral refixation. *J Bone Joint Surg Am.* May 2006; 88(5): 925-35. PMID 16651565
17. Peters CL, Erickson JA. Treatment of femoro-acetabular impingement with surgical dislocation and débridement in young adults. *J Bone Joint Surg Am.* Aug 2006; 88(8): 1735-41. PMID 16882895
18. Beck M, Leunig M, Parvizi J, et al. Anterior femoroacetabular impingement: part II. Midterm results of surgical treatment. *Clin Orthop Relat Res.* Jan 2004; (418): 67-73. PMID 15043095
19. Jan K, Fenn TW, Kaplan DJ, et al. Patients Maintain Clinically Significant Outcomes at 5-Year Follow-Up After Hip Arthroscopy for Femoroacetabular Impingement Syndrome: A Systematic Review. *Arthroscopy.* Aug 2023; 39(8): 1869-1881.e1. PMID 37207920
20. Lamo-Espinosa JM, Mariscal G, Gómez-Álvarez J, et al. Efficacy and safety of arthroscopy in femoroacetabular impingement syndrome: a systematic review and meta-analysis of randomized clinical trials. *Sci Rep.* Oct 01 2023; 13(1): 16493. PMID 37779117
21. Dwyer T, Whelan D, Shah PS, et al. Operative Versus Nonoperative Treatment of Femoroacetabular Impingement Syndrome: A Meta-analysis of Short-Term Outcomes. *Arthroscopy.* Jan 2020; 36(1): 263-273. PMID 31864588
22. Casartelli NC, Valenzuela PL, Maffiuletti NA, et al. Effectiveness of Hip Arthroscopy on Treatment of Femoroacetabular Impingement Syndrome: A Meta-Analysis of Randomized Controlled Trials. *Arthritis Care Res (Hoboken).* Aug 2021; 73(8): 1140-1145. PMID 32339441
23. Minkara AA, Westermann RW, Rosneck J, et al. Systematic Review and Meta-analysis of Outcomes After Hip Arthroscopy in Femoroacetabular Impingement. *Am J Sports Med.* Feb 2019; 47(2): 488-500. PMID 29373805



24. Kierkegaard S, Langeskov-Christensen M, Lund B, et al. Pain, activities of daily living and sport function at different time points after hip arthroscopy in patients with femoroacetabular impingement: a systematic review with meta-analysis. *Br J Sports Med.* Apr 2017; 51(7): 572-579. PMID 27845683
25. Krych AJ, Thompson M, Knutson Z, et al. Arthroscopic labral repair versus selective labral debridement in female patients with femoroacetabular impingement: a prospective randomized study. *Arthroscopy.* Jan 2013; 29(1): 46-53. PMID 23276413
26. Palmer A, Fernquest S, Rombach I, et al. Medium-term results of arthroscopic hip surgery compared with physiotherapy and activity modification for the treatment of femoroacetabular impingement syndrome: a multi-centre randomised controlled trial. *Br J Sports Med.* Jan 02 2025; 59(2): 109-117. PMID 39592214
27. Zhang D, Chen L, Wang G. Hip arthroscopy versus open surgical dislocation for femoroacetabular impingement: A systematic review and meta-analysis. *Medicine (Baltimore).* Oct 2016; 95(41): e5122. PMID 27741133
28. Nwachukwu BU, Rebolledo BJ, McCormick F, et al. Arthroscopic Versus Open Treatment of Femoroacetabular Impingement: A Systematic Review of Medium- to Long-Term Outcomes. *Am J Sports Med.* Apr 2016; 44(4): 1062-8. PMID 26059179
29. Matsuda DK, Carlisle JC, Arthurs SC, et al. Comparative systematic review of the open dislocation, mini-open, and arthroscopic surgeries for femoroacetabular impingement. *Arthroscopy.* Feb 2011; 27(2): 252-69. PMID 21266276
30. Botser IB, Smith TW, Nasser R, et al. Open surgical dislocation versus arthroscopy for femoroacetabular impingement: a comparison of clinical outcomes. *Arthroscopy.* Feb 2011; 27(2): 270-8. PMID 21266277
31. Papalia R, Del Buono A, Franceschi F, et al. Femoroacetabular impingement syndrome management: arthroscopy or open surgery?. *Int Orthop.* May 2012; 36(5): 903-14. PMID 22190060
32. Wu CT, Mahameed M, Lin PC, et al. Treatment of cam-type femoroacetabular impingement using anterolateral mini-open and arthroscopic osteochondroplasty. *J Orthop Surg Res.* Jul 17 2019; 14(1): 222. PMID 31315654
33. Chiron P, Espié A, Reina N, et al. Surgery for femoroacetabular impingement using a minimally invasive anterolateral approach: analysis of 118 cases at 2.2-year follow-up. *Orthop Traumatol Surg Res.* Feb 2012; 98(1): 30-8. PMID 22257764
34. Laude F, Stimesi E, Nogier A. Femoroacetabular impingement treatment using arthroscopy and anterior approach. *Clin Orthop Relat Res.* Mar 2009; 467(3): 747-52. PMID 19089524
35. Huang HJ, Zhou X, Huang ZG, et al. Arthroscopic Treatment for Femoroacetabular Impingement Syndrome in Adolescents: A Systematic Review and Meta-Analysis. *Clin J Sport Med.* Nov 01 2022; 32(6): 608-616. PMID 36315820
36. Guindani N, Eberhardt O, Wirth T, et al. Surgical dislocation for pediatric and adolescent hip deformity: clinical and radiographical results at 3 years follow-up. *Arch Orthop Trauma Surg.* Apr 2017; 137(4): 471-479. PMID 28197752
37. Nwachukwu BU, Chang B, Kahlenberg CA, et al. Arthroscopic Treatment of Femoroacetabular Impingement in Adolescents Provides Clinically Significant Outcome Improvement. *Arthroscopy.* Oct 2017; 33(10): 1812-1818. PMID 28623078
38. Tran P, Pritchard M, O'Donnell J. Outcome of arthroscopic treatment for cam type femoroacetabular impingement in adolescents. *ANZ J Surg.* May 2013; 83(5): 382-6. PMID 22943465
39. Oduwale KO, de Sa D, Kay J, et al. Surgical treatment of femoroacetabular impingement following slipped capital femoral epiphysis: A systematic review. *Bone Joint Res.* Aug 2017; 6(8): 472-480. PMID 28790036
40. Sink EL, Zaltz I, Heare T, et al. Acetabular cartilage and labral damage observed during surgical hip dislocation for stable slipped capital femoral epiphysis. *J Pediatr Orthop.* 2010; 30(1): 26-30. PMID 20032738



41. Ziebarth K, Zilkens C, Spencer S, et al. Capital realignment for moderate and severe SCFE using a modified Dunn procedure. *Clin Orthop Relat Res*. Mar 2009; 467(3): 704-16. PMID 19142692
42. Spencer S, Millis MB, Kim YJ. Early results of treatment of hip impingement syndrome in slipped capital femoral epiphysis and pistol grip deformity of the femoral head-neck junction using the surgical dislocation technique. *J Pediatr Orthop*. 2006; 26(3): 281-5. PMID 16670535
43. O'Connor M, Steidl GK, Padaki AS, et al. Outcomes of Revision Hip Arthroscopic Surgery: A Systematic Review and Meta-analysis. *Am J Sports Med*. Apr 2020; 48(5): 1254-1262. PMID 31503501
44. Sardana V, Philippon MJ, de Sa D, et al. Revision Hip Arthroscopy Indications and Outcomes: A Systematic Review. *Arthroscopy*. Oct 2015; 31(10): 2047-55. PMID 26033461
45. Cvetanovich GL, Harris JD, Erickson BJ, et al. Revision Hip Arthroscopy: A Systematic Review of Diagnoses, Operative Findings, and Outcomes. *Arthroscopy*. Jul 2015; 31(7): 1382-90. PMID 25703289
46. Lynch TS, Minkara A, Aoki S, et al. Best Practice Guidelines for Hip Arthroscopy in Femoroacetabular Impingement: Results of a Delphi Process. *J Am Acad Orthop Surg*. Jan 15 2020; 28(2): 81-89. PMID 31181030
47. National Institute for Health and Clinical Excellence (NICE). Arthroscopic femoro-acetabular surgery for hip impingement syndrome [IPG408]. 2011; <https://www.nice.org.uk/guidance/IPG408>. Accessed May 8, 2025.
48. National Institute for Health and Care Excellence (NICE). Open femoro-acetabular surgery for hip impingement syndrome [IPG403]. 2011; <https://www.nice.org.uk/guidance/IPG403>. Accessed May 8, 2025.

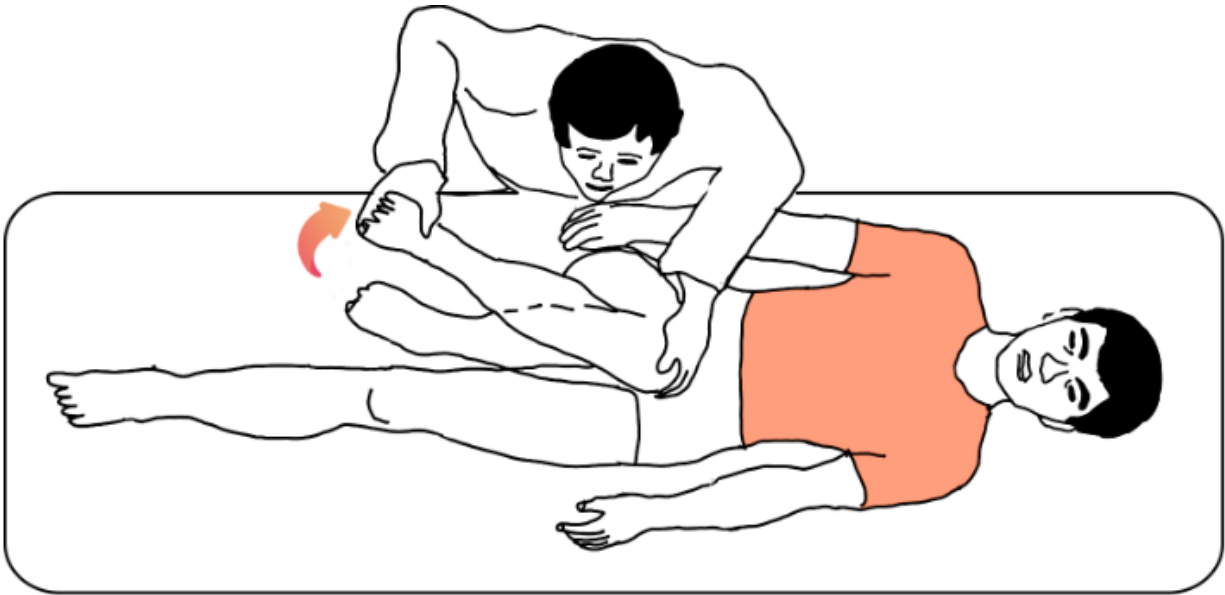
## Appendix

### Impingement Test

As part of the physical examination, your doctor will likely conduct the impingement test. For this test, your doctor will bring your knee up toward your chest and then rotate it inward toward your opposite shoulder. If this re-creates your hip pain, the test result is positive for impingement.

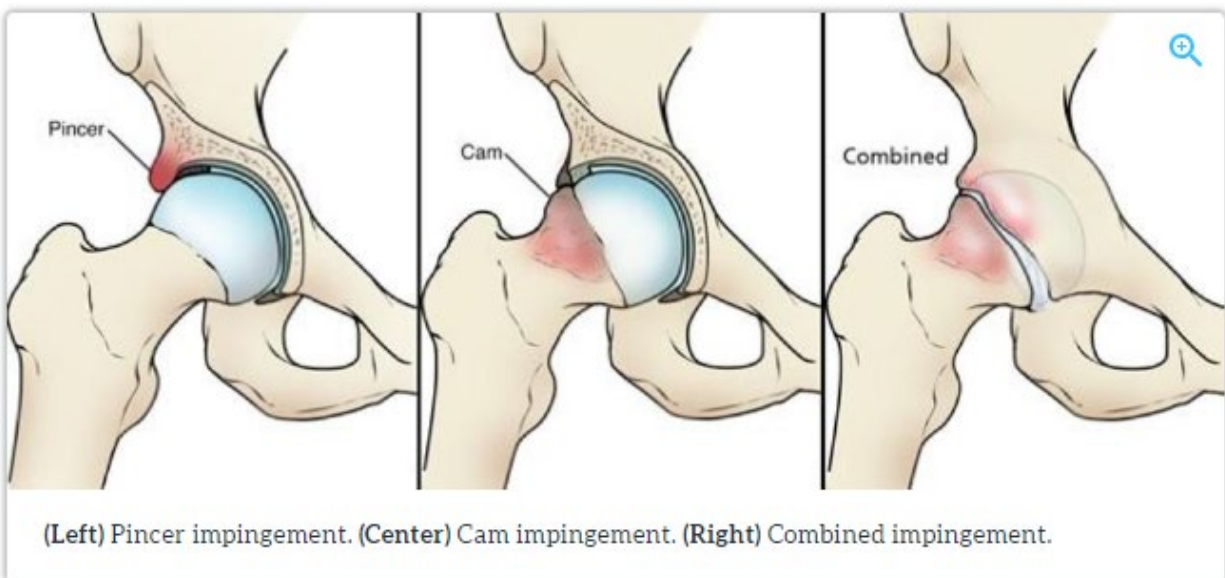






Source: <https://www.uprighthealth.com/fai-tests>. Accessed June 3, 2025.

Types of FAI



Source: <https://orthoinfo.aaos.org/en/diseases--conditions/femoroacetabular-impingement/> Accessed June 3, 2025.

## History

Date	Comments
02/08/11	Add to Surgery section. - New Policy replacing PR.7.01.539.
07/12/11	Replace Policy - Policy updated with literature review through February 2011; references added and reordered; policy statements unchanged. ICD-10 codes added to policy.
07/20/12	Replace policy. Policy updated with literature review through February 2012; references 2, 24 and 34 added. Policy statement is unchanged.
09/25/12	Update Coding Section – ICD-10 codes are now effective 10/01/2014.
12/20/12	Update Related Policies – Remove 7.01.530 as it was archived.
03/15/13	Update Related Policies. Add 2.01.31.
05/28/13	Minor update. Definitions for FABER and FADIR tests added to the Appendix section; no other changes.
07/08/13	Archive policy. Policy statement has clarified skeletally mature age & removed age restriction on older adults. Rationale updated based on a literature review through April 2013, References 4, 11, 15-17, 19, 22, 31 added; others renumbered/removed.

Date	Comments
	Definitions added to appendix for Tonnis and Outerbridge classification of OA. Policy statement changed as noted.
07/01/24	New policy 7.01.592 Surgical Treatment of Femoroacetabular Impingement replaces previously archived policy 7.01.118 Surgical Treatment of Femoroacetabular Impingement, approved June 11, 2024. The following policy changes are effective on or after October 8, 2024, following 90-day provider notification. Policy updated with literature review through February 9, 2024; references added. Open or arthroscopic treatment of femoroacetabular impingement (FAI) may be considered medically necessary when criteria are met. Added CPT codes 29914-29916.
12/01/24	Interim Review, approved November 11, 2024. Minor edit for clarity only, policy intent unchanged. CPT code 29916 removed from policy for clarity.
07/01/25	Annual Review, approved June 23, 2025. Policy updated with literature review through February 21, 2025; reference added. Policy statements unchanged.

**Disclaimer:** This medical policy is a guide in evaluating the medical necessity of a particular service or treatment. The Company adopts policies after careful review of published peer-reviewed scientific literature, national guidelines and local standards of practice. Since medical technology is constantly changing, the Company reserves the right to review and update policies as appropriate. Member contracts differ in their benefits. Always consult the member benefit booklet or contact a member service representative to determine coverage for a specific medical service or supply. CPT codes, descriptions and materials are copyrighted by the American Medical Association (AMA). ©2025 Premera All Rights Reserved.

**Scope:** Medical policies are systematically developed guidelines that serve as a resource for Company staff when determining coverage for specific medical procedures, drugs or devices. Coverage for medical services is subject to the limits and conditions of the member benefit plan. Members and their providers should consult the member benefit booklet or contact a customer service representative to determine whether there are any benefit limitations applicable to this service or supply. This medical policy does not apply to Medicare Advantage.

